

**COMUNE DI CASTEL MAGGIORE (BO)**

**Miglioramento Sismico -  
Scuola dell' Infanzia del  
Capoluogo "M. Mezzetti"**  
Via della Costituzione, 54  
**PROGETTO ESECUTIVO**

**Il Progettista**  
Ing. VITO MARCHIONNA

**il Committente**

**Pareri Enti competenti**

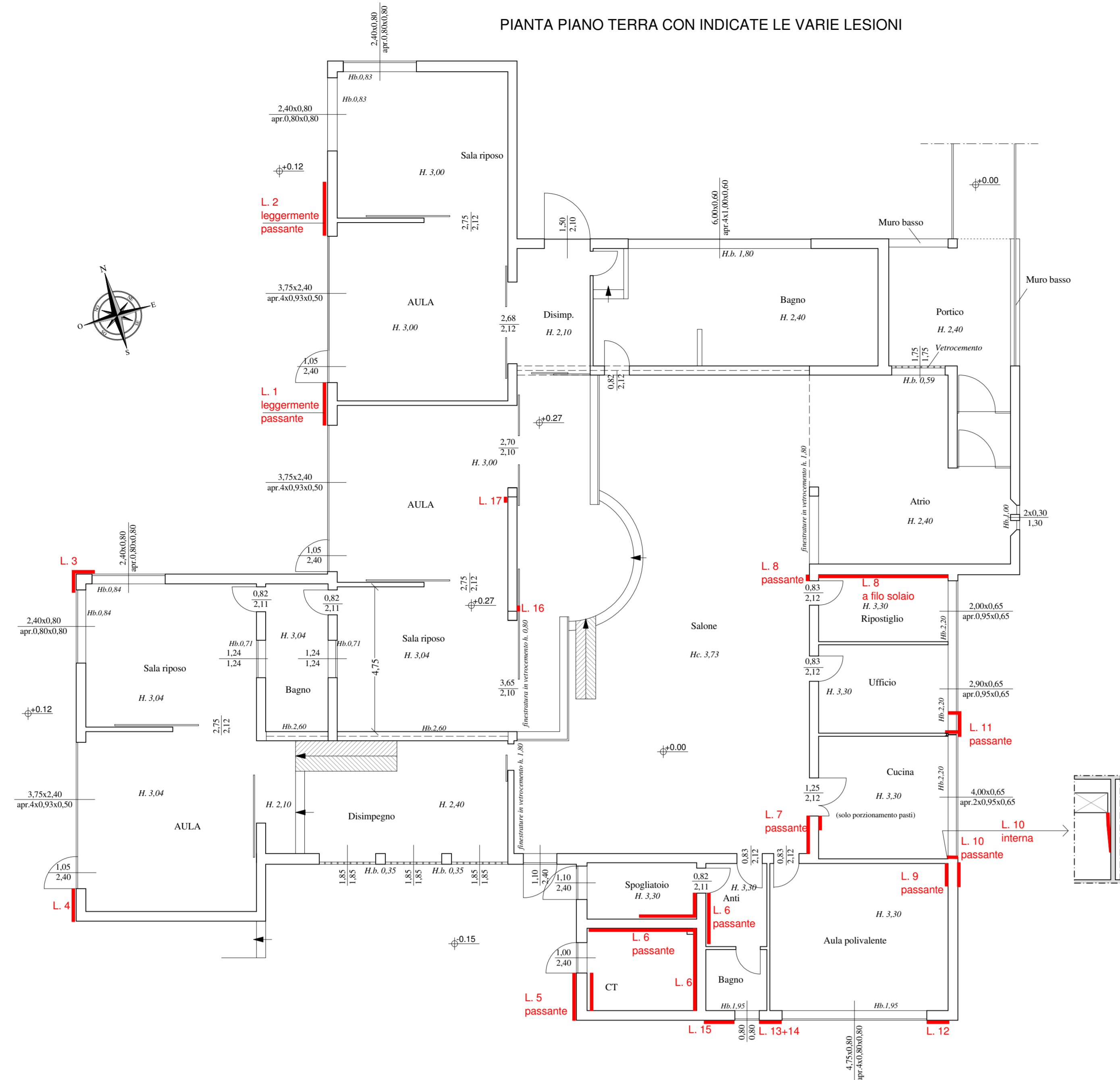
**oggetto : rilievo delle lesioni (al 24/06/2020)**

**scala : 1:100**

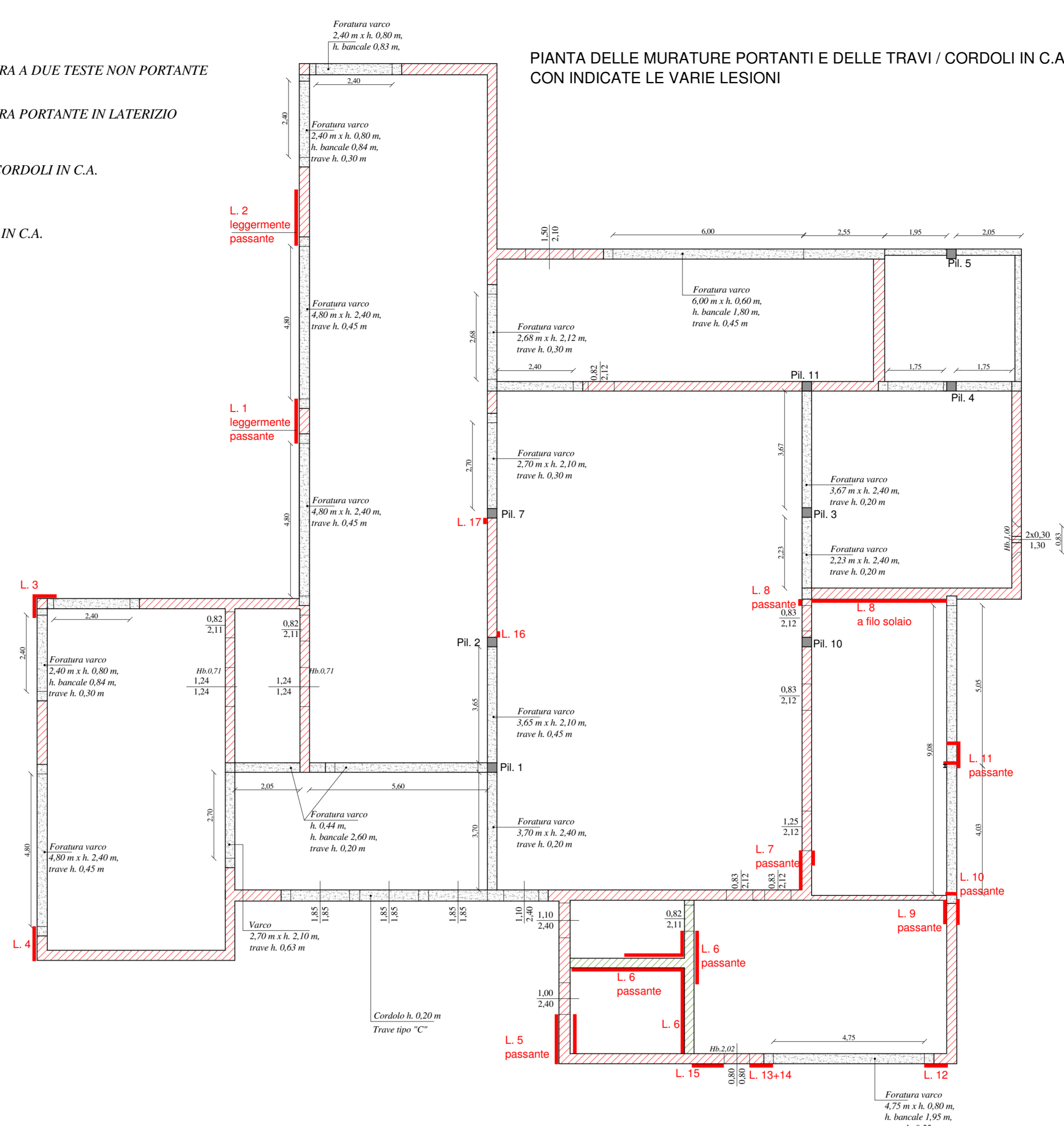
**data : novembre 2020**

**Elaborato**

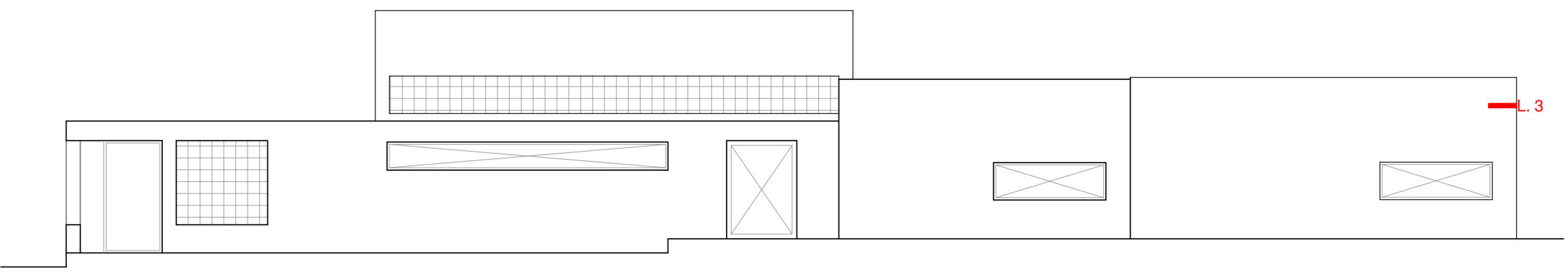
**EL A02**



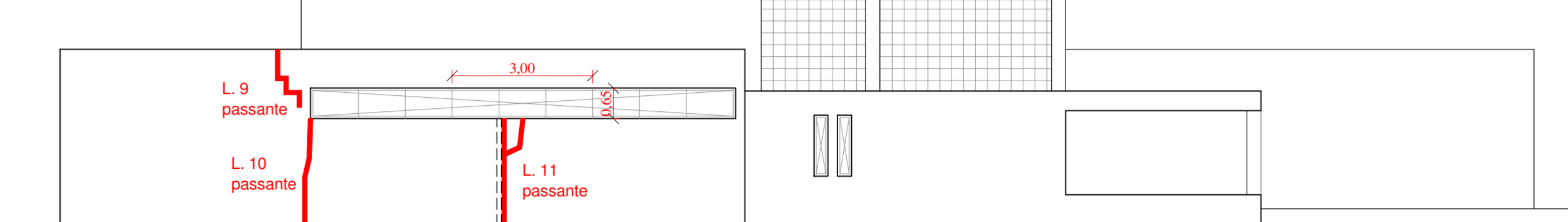
- MURATURA A DUE TESTE NON PORTANTE
- MURATURA PORTANTE IN LATERIZIO
- TRAVI E CORDOLI IN C.A.
- PIALTRI IN C.A.
- LESIONI



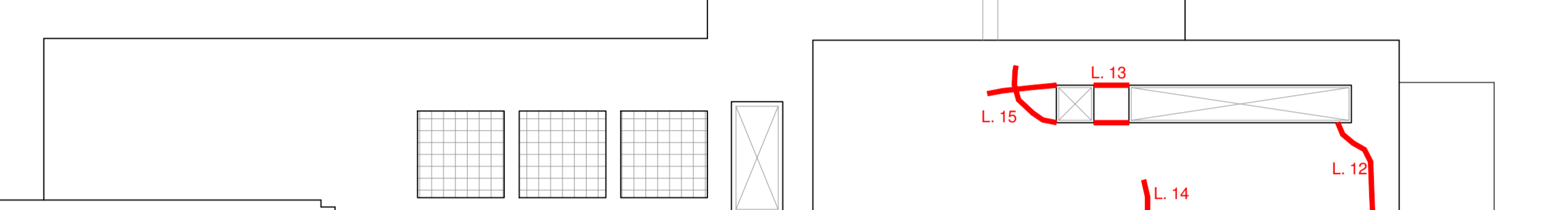
PROSPETTO NORD - SCHEMATICO -  
CON INDICATE LE VARIE LESIONI



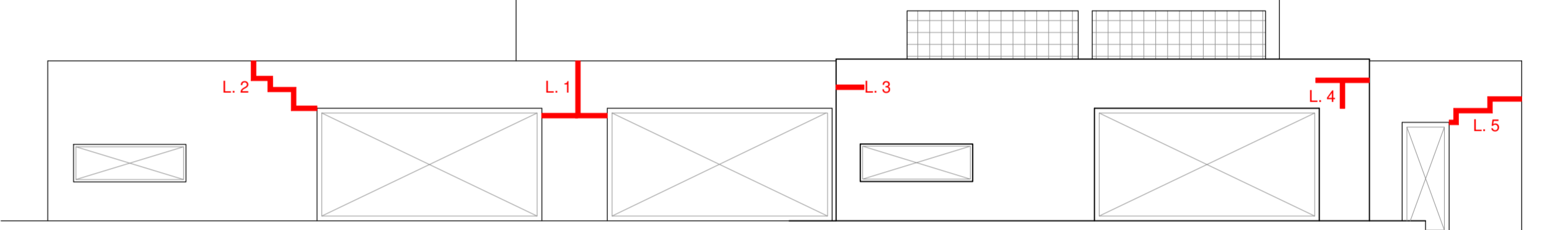
PROSPETTO EST - SCHEMATICO -  
CON INDICATE LE VARIE LESIONI



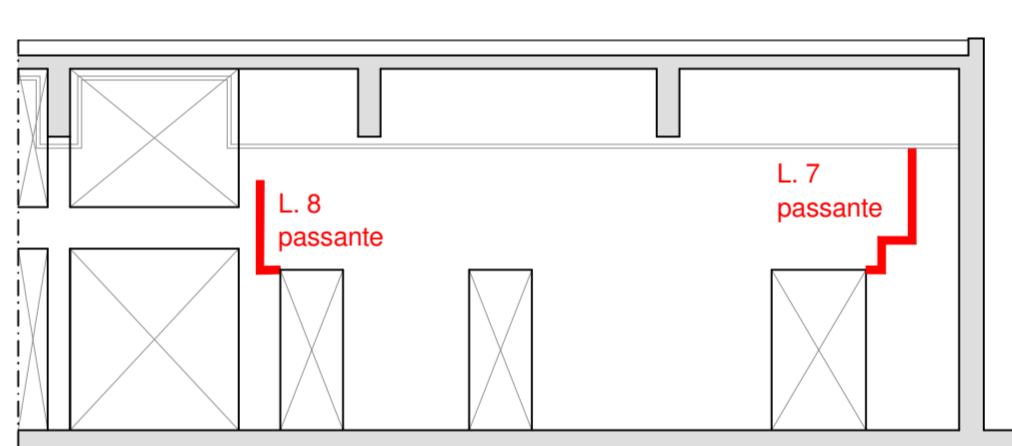
PROSPETTO SUD - SCHEMATICO -  
CON INDICATE LE VARIE LESIONI



PROSPETTO OVEST - SCHEMATICO -  
CON INDICATE LE VARIE LESIONI



STRALCIO SCHEMATICO SEZIONE LONGITUDINALE  
SALONE - VERSO ZONA INGRESSO - CON INDICATE LE VARIE LESIONI



STRALCIO SCHEMATICO SEZIONE LONGITUDINALE  
SALONE - VERSO ZONA AULE - CON INDICATE LE VARIE LESIONI

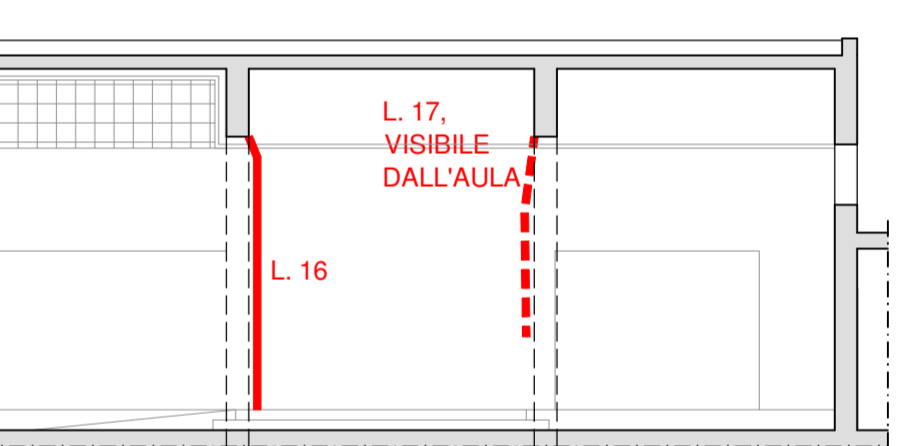


FOTO LESIONE 1




FOTO LESIONE 2




FOTO LESIONE 3



FOTO LESIONE 4



FOTO LESIONE 5 - esterno




FOTO LESIONE 5 - interno



FOTO LESIONE 6 - lato CT (confine bagno)



FOTO LESIONE 6 - lato CT (confine spogliatoio)



FOTO LESIONE 6 - lato spogliatoio (confine Anti. - CT)




FOTO LESIONE 6 - latoAnti. (confine spogliatoio - CT)



FOTO LESIONE 7 - lato Salone




FOTO LESIONE 7 - lato Cucina



FOTO LESIONE 8 - lato Salone




FOTO LESIONE 8 - lato Ripostiglio




FOTO LESIONE 8 - solaio Ripostiglio



FOTO LESIONE 9




FOTO LESIONE 9 - interno




FOTO LESIONE 10




FOTO LESIONE 10 - interno




FOTO LESIONE 11



FOTO LESIONE 11 - interno




FOTO LESIONE 11 - interno




FOTO LESIONE 11 - interno




FOTO LESIONE 12



FOTO LESIONE 13




FOTO LESIONE 14




FOTO LESIONE 15



FOTO LESIONE 16




FOTO LESIONE 17



FOTO LESIONE TIPICA CORRENTE ORIZZONTALE  
TRA CORDOLO E SOLAIO DI COPERTURA

